

RADIAL SHOCKWAVE THERAPY AFTER CRYOLIPOLYSE™ FOR CELLULITE AND LYMPHEDEMA - A FIELD

DR. MED. MATTHIAS SANDHOFER, HAUT-ÄSTHETIK-LASER-VENENZENTRUM, LINZ, 02/2015

KEYWORDS: Cellulite, cryolipolysis, lymphedema, radial shockwave therapy

SUMMARY

When one combines the cryolipolysis with the *Z Wave^{Pro}* treatment, fat reduction as well as skin tightening is improved. Also the treatment of cellulite delivers convincing results coupled with a high patient acceptability – the therapy is pleasant and the skin feels smooth and even.

With the decongestion of a decompensated lymphedema, the time of being free of symptoms, can be decisively prolonged compared to manual and mechanical lymph drainage. Altogether the *Z Wave^{Pro}* treatment is ideal for decongestion and surface profiling of the dermal subcutaneous zone. This evidence is also backed by our not yet published results regarding stem cells in the dermal and subcutaneous fatty tissue.




Fig. 1: Since one and a half year the shockwave therapy system *Z Wave^{Pro}* from Zimmer MedizinSysteme GmbH, Neu-Ulm is used constantly in our health center

INTRODUCTION

Radial shock waves are high energy sound waves generated electromagnetically outside the body. They are introduced through the skin surface into the human tissue and spread there in radial (spherical) form. The treatment is perceived as particularly gentle due to this radial propagation. After treatment, the tissue responds to the shock wave with increased metabolic activity. As a result, the epidermis becomes tightened.

Likewise, the acoustic waves stimulate blood circulation, neovascularization, and the production of collagen. The improved metabolism and blood flow accelerate the removal of lymph.

The shockwave therapy system *Z Wave^{Pro}* from the company Zimmer MedizinSysteme GmbH, Neu-Ulm, has been in routine use in our community practice for one and a half years now.

COMBINATION WITH CRYOLIPOLYSE™

Studies have shown that a shock wave treatment immediately after Cryolipolyse™ can double the success of treatment in terms of fat reduction. Besides improving fat reduction, improved skin tightening can also be expected.

In our practice we use the shock wave therapy for the resorption of the damaged fat cells; very often we combine the use of radio frequency for additional tightening.

Cryolipolyse™ in the abdominal region, in combination with radio frequency (VelaShape™) and the ZWave^{Pro}.

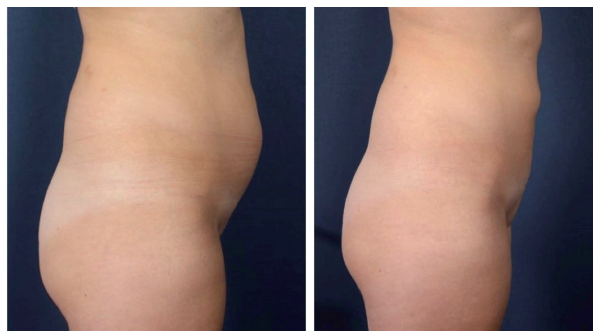

Fig. 2a + b: Cryolipolysis™ of the abdominal region, in combination with radio frequency (VelaShape™) and the ZWave^{Pro} before treatment (a) and after 4 weeks (b)

CELLULITE

People with cellulite suffer it due to a weakness of the connective tissue fibres, with prolapse of septa in the subcutaneous adipose tissue, mainly in the areas of thighs, upper arms, hips, buttocks, and stomach. This then causes a dimpling of the skin surface. This occurs almost exclusively in women, since men have a different connective tissue networking in adipose tissue. Cellulite can occur in young adults if they are overweight and/or have weak connective tissue, and with advancing age these changes can be found in 80 to 90 percent of women to varying degrees.

We combine the cellulite treatment using shock waves with radio frequency, and additional muscle exercises, especially of the gluteal muscles and thigh region.

Combined cellulite treatment on the hip and buttock region with radio frequency (VelaShape™) and the ZWave^{Pro}

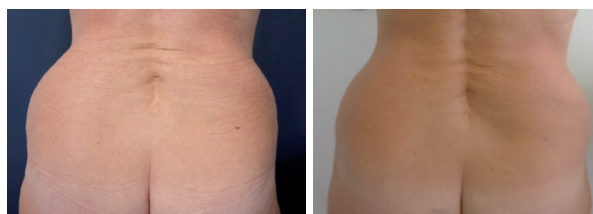

Fig. 3a + b: Combined cellulite treatment of hip and buttock region with radio frequency (VelaShape™) and the ZWave^{Pro} before treatment (10 times in 10 weeks)

LYMPHEDEMA

Shockwave therapy has proven to be very effective for decongestion in decompensated lipodema. Freedom from symptoms could be extended by 3 -7 days in contrast to manual and instrumental lymph drainage.

Among other things, primary lymphedema was treated lymphologically, whereby even an up to two-week application achieved both complete freedom from symptoms, and significant reduction in volume.

Secondary lymphedema after varicose vein surgery, and also temporary local lymphatic induration after miniphlebectomy, responded well to ZWave^{Pro} treatment.

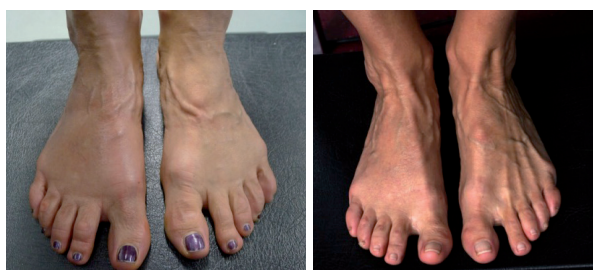

Fig. 4a + b: Secondary lymphedema of the right forefoot after variceal surgery before and after 10 treatments (1-2 times a week)

Literature

1. Stieger M, Schmid JP, Bajrami S, Hunziker T (2013) Extrakorporale Stoßwellentherapie eines komplizierten chronischen Ulcus cruris venosum. *Hautarzt* 64: 443-446.
2. Kuhn C, Angehrn F, Sonnabend O, Voss A (2008) Impact of extracorporeal shock waves on the human skin with cellulite: A case study of an unique instance. *Clin Interv Aging* 3: 201-210.
3. Sandhofer M, Sandhofer M, Sandhofer-Novak, R, Schauer P (2013): Kryolipolyse in der dermatologischen Praxis. *Kosmet Med* 34: 13: 100-109.

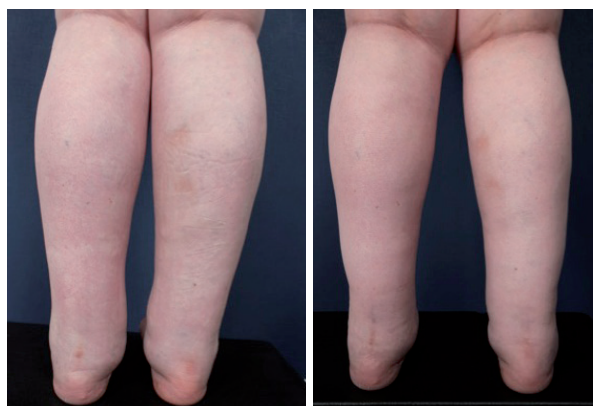


Fig. 5a + b: Primary lymphedema painful (after treatment- complete freedom from symptoms and significant scope reduction) before and after 10 treatments (1-2 times a week)