

M. Sandhofer et al.

Effective nonsurgical body contouring through combined treatment of cryolipolysis, injection lipolysis, and shock wave

Matthias Sandhofer¹, Patrick Schauer², Jörg Faulhaber³

¹A-4020 Linz, Starhembergerstr. 12, www.sandhofer.at

²D-94032 Passau, Bahnhofstraße 8, www.hautarzt-passau.com

³D-73525 Schwäbisch Gmünd, Kalter Markt 27, www.hautarzt-gmuend.de

Key Words

apoptosis, non invasive body contouring, sub-cutaneous fat, injection lipolysis, shock wave, cryolipolysis, brown, beige, white fat, cryolipothermia

Abstract

The histological tissue reaction following a cryolipolysis treatment has been used to select really effective

cryolipolysis procedures available on the market.

After that, the tissue reaction following a combination treatment (cryolipolysis, injection lipolysis, and shock waves) has been histologically quantified. Significantly improved results make this combination treatment highly recommendable for everyday application in practice.

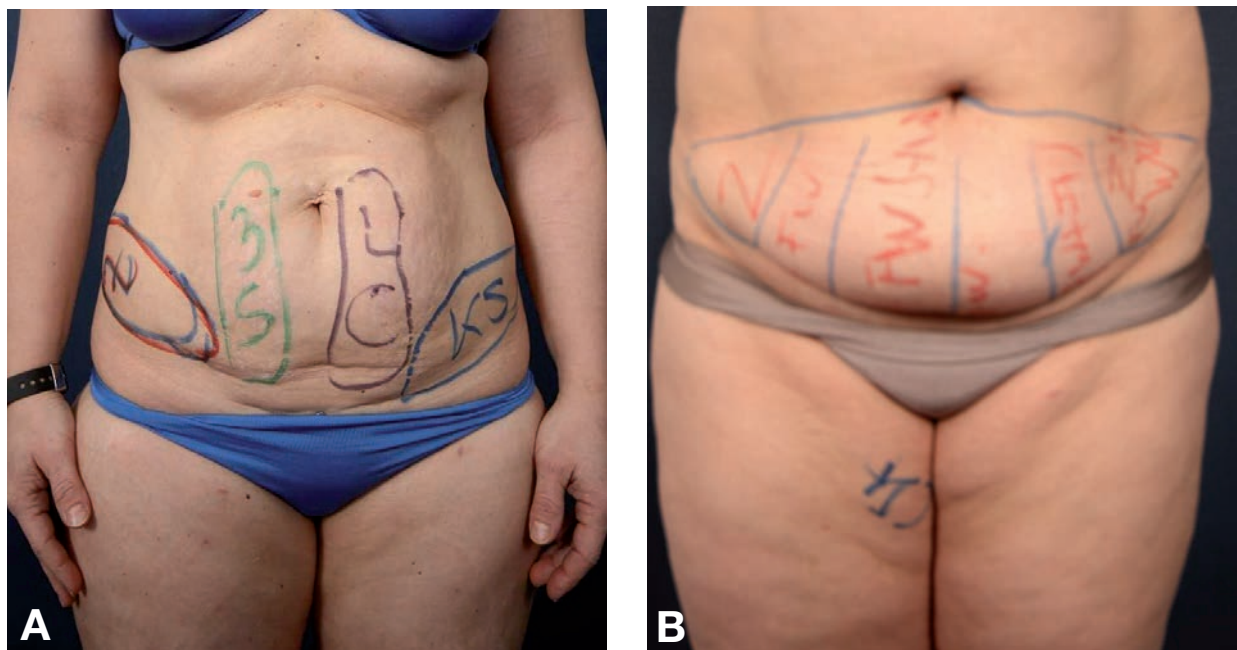


Figure 1a-b: (A) Planning of cryolipolysis therapy at lower abdomen of the patient 15 days prior to performing the Avelar Technique, (B) Planning of combination treatment cryolipolysis, injection lipolysis, and shock wave 14 days prior to performing tummy tuck procedure.

In recent years, cryolipolysis has proven to be a very effective technology in nonsurgical body contouring. Since the initial presentation by Dieter Manstein the apoptosis is known as a mechanism for fat reduction. This was backed up by histological data [1]. The studies demonstrate that after approx. 14 days the damage to the adipocytes and the associated phagocytic reaction can be objectivised best from the histological point of view. During the last few years a great number of devices were accepted on the market without showing their histological effect.

In several preliminary investigations we have analysed the efficacy of various devices under clinical and histological aspects. After that the possible combination of cryolipolysis with injection lipolysis and radial shock wave has been explored.

Patients and Methods

6 female patients with a so-called "stomach apron" were treated 15 days before a scheduled Avelar abdominoplasty [2] by means of different cryolipolysis devices. For the first 3 patients a total of 6 cryolipolysis devices were applied (2015; figure 1). After tummy tuck, histological examinations

have been performed. The specimens were processed by 2 independent pathologists and damage of the adipocytes and the phagocytic reaction was evaluated (0 to +++).

In 2016 three patients with "stomach apron" were treated by using 2 cryolipolysis devices alone and in combination with injection lipolysis (Compound Network, dilution 50% NWL1 / 50% NWL 2; 10-20 ml depending on the treatment area) (figure 2) and/or radial shock wave therapy (Zimmer Medizin-Systeme, Neu-Ulm) (figure 3). The radial shock wave (Z Wave Pro) had been applied at 16 Hz and 120 mJ. 22 patients were treated in the abdominal region whereas possible seasonal fluctuations with regard to body fat distribution have been controlled by means of the Tanita monitor. In addition, abdominal girth measurements and measurements of the abdominal layer thickness have been effected by means of Duplex sonography before treatment as well as 3 months after treatment.

In addition, these patients were treated with a further local shock wave therapy 2 and 4 weeks after initial treatment in order to optimize the phagocytic reaction of the damaged tissue [3,4].

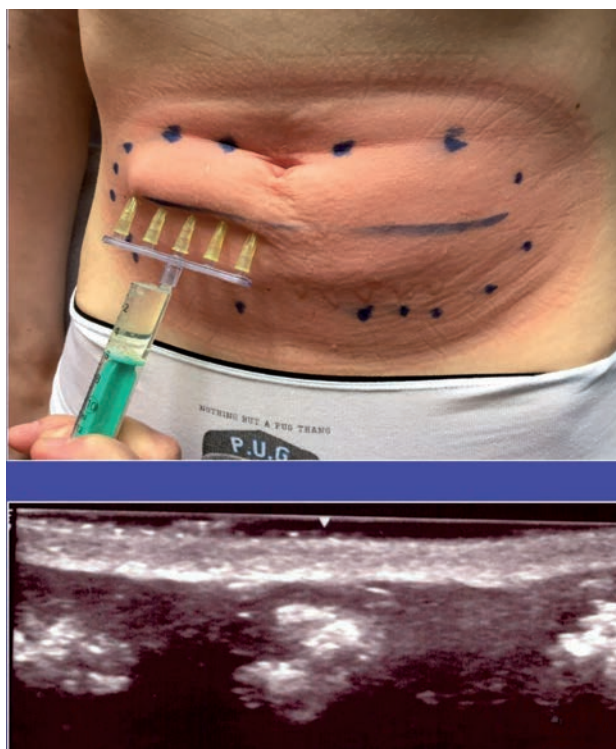


Figure 2: Injection lipolysis after previous cryolipolysis and presentation of compound distribution (network) via Duplex sonography directly after injection.

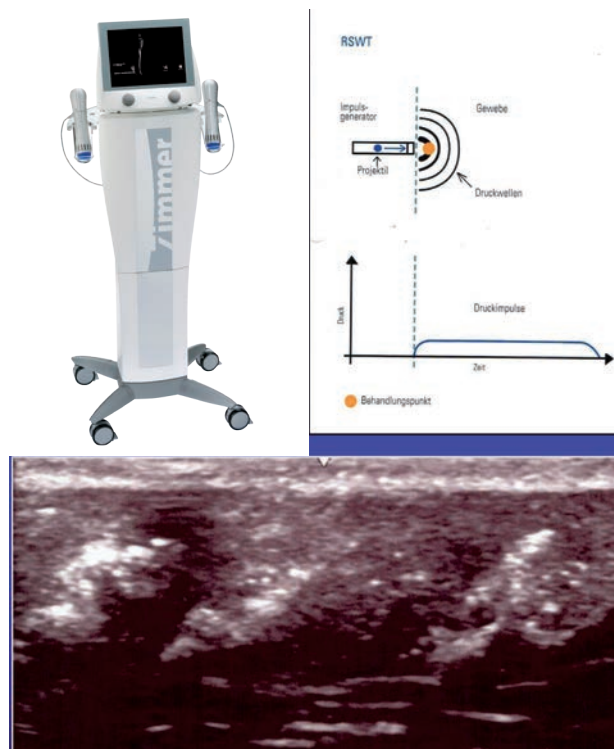


Figure 3: Diffuse distribution of compound directly after radial shock wave therapy (Z Wave Pro, Zimmer MedizinSysteme).

Results

1. Histological Outcomes

As for the histological examinations of the equipment only the original patent (Zeltiq Inc., Coolsculpting), as well as a second device with an efficacy of ++ were assessed in 2015 by 2 independent pathologists with regard to cell damage and phagocytic reaction. For the other 4 devices no evidence of significant histological effectiveness could be provided.

2 cryolipolytic devices (Zeltiq Inc. and Z Lipo, Zimmer MedizinSysteme) were tested on the other 3 patients (2016) – alone and in combination with and without radial shock wave treatment. The Zeltiq device alone was once again rated at ++. The Z Lipo device from Zimmer MedizinSysteme had been evaluated in relation to the sole effect ++ by independent histo-pathologists. The combination with radiant shock waves and injection lipolysis showed maximum effect (+++) for both devices in terms of apoptosis and phagocytosis (figure 4).

2. Clinical Outcomes

Patients at a stable body weight achieved outstanding results

that came close to a surgical treatment (liposuction) (figure 5). No significant adverse events compared to monotherapy [5] have been reported. Merely 3 cases of small lumps with moderate tenderness and temporary hyperpigmentation in the injection area occurred (figure 6) which resolved within 3–4 months after treatment.

16 patients reported a positive perception equivalent to “very good” on the grading scale from 1 (very good) to 6 (insufficient), three patients rated the outcome “good” and 3 patients were dissatisfied with the outcome (grade 6). A simultaneous impedance analysis with the Tanita monitor which allowed precise weight measurement showed a weight gain for the dissatisfied patients during the summer months.

Discussion

Cryolipolysis as a novel nonsurgical method has marked a new era in body contouring practice in which the apoptosis (cryolipolysis + apoptosis: CrApo) plays a crucial role and stands out clearly from common methods as far as efficacy is concerned. Trials with combined applications have proven their worth already in advance [4,6,7,8].

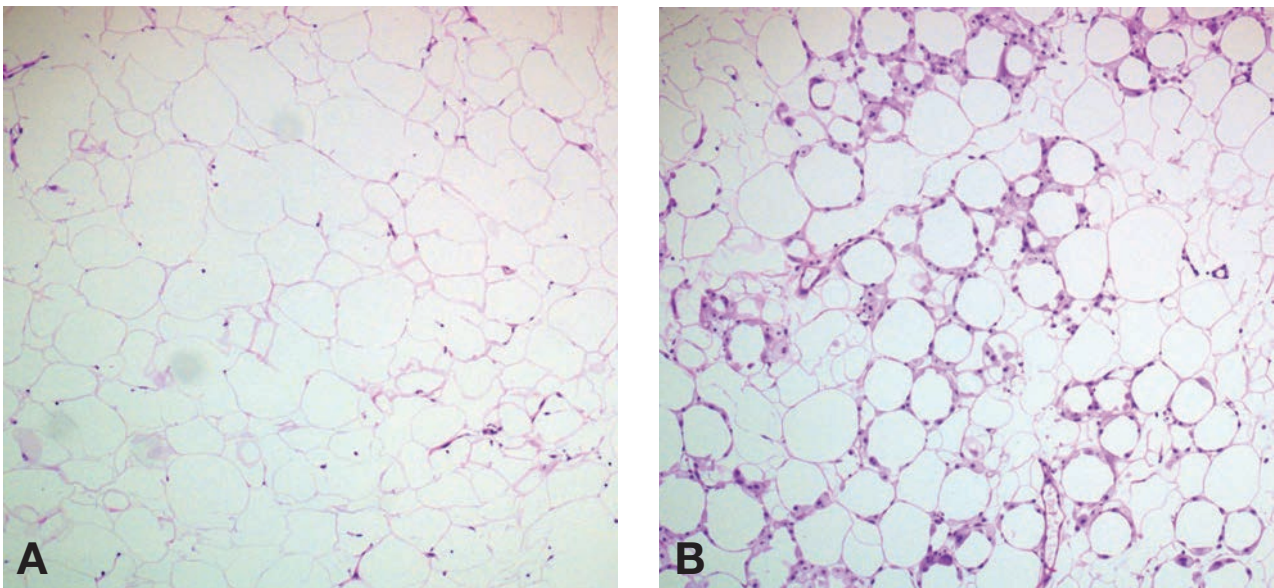


Figure 4a-b: (A) Histology after sole application of cryolipolysis (Z Lipo, Zimmer MedizinSysteme); (B) significant increase of efficacy after cryolipolysis (Z Lipo, Zimmer MedizinSysteme), injection lipolysis and shock wave distribution (Z Wave Pro, Zimmer MedizinSysteme).

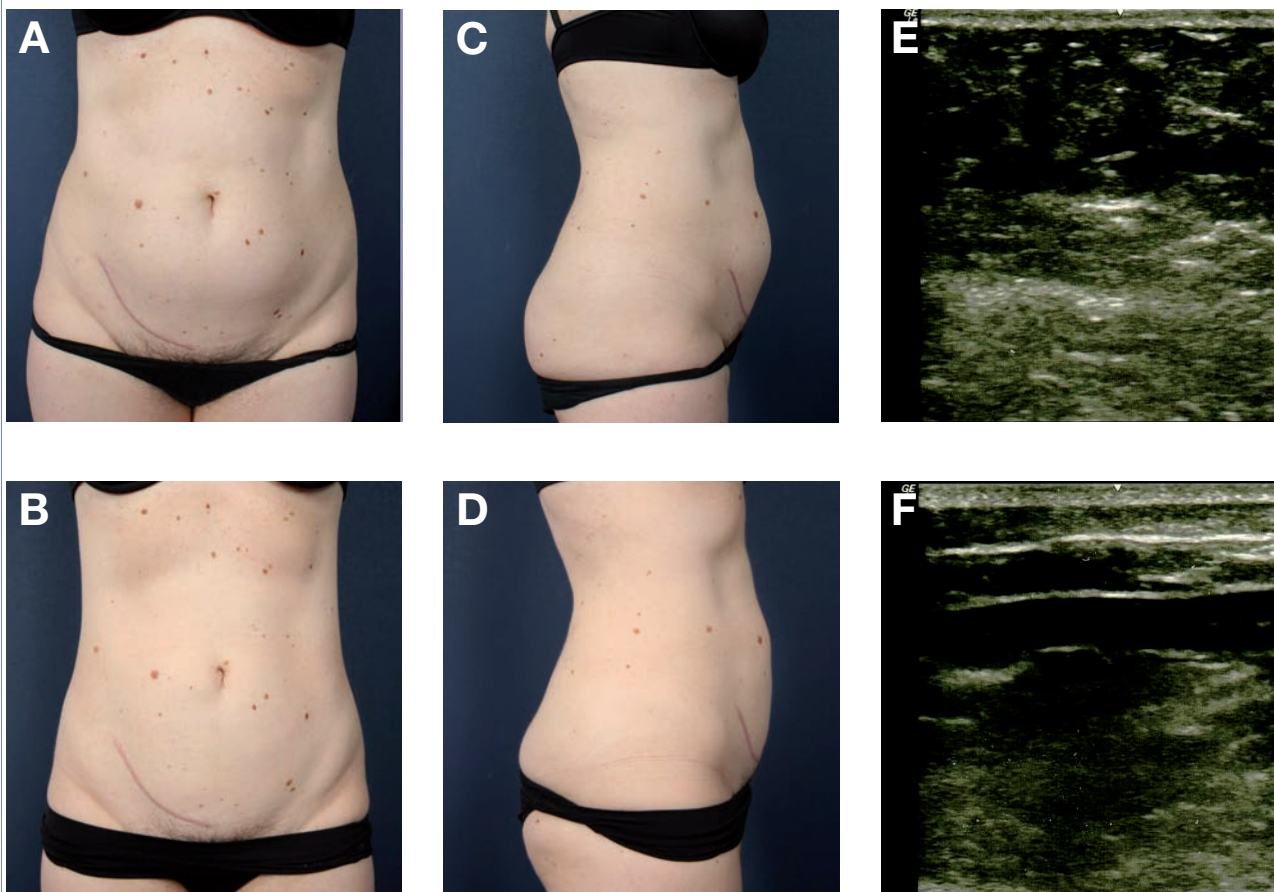


Figure 5a-f: (A) frontal view before treatment, (B) frontal view 3 months after treatment, (C) lateral view before treatment, (D) lateral view 3 months after treatment, (E) Duplex sonography before treatment, (F) Duplex sonography 3 months after treatment with a layer thickness reduction of approx. 1.5 cm.

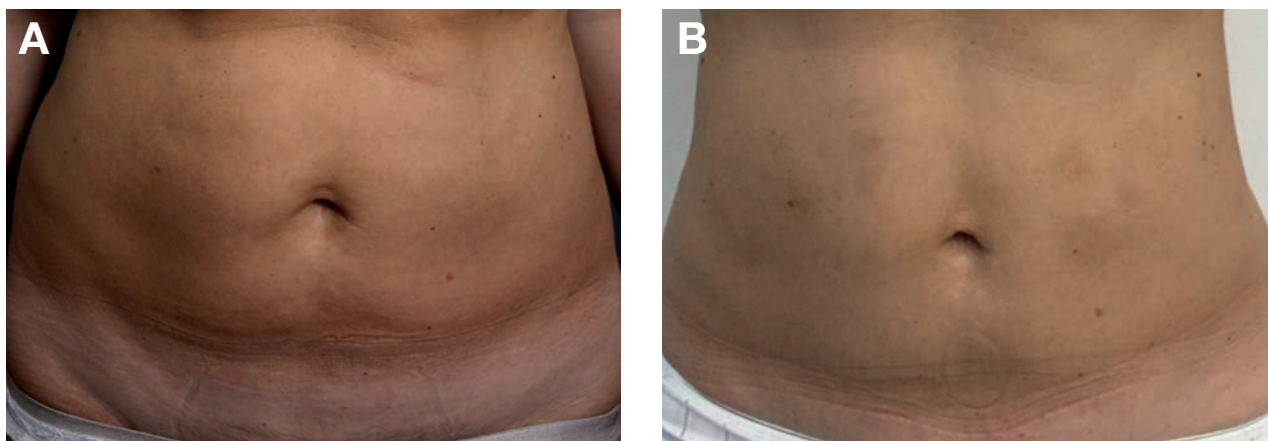


Figure 6a-b: (A) frontal view before treatment, (B) frontal view with hyperpigmentation after 6 weeks. Hyperpigmentation resolved after 4 months.

Due to the “European admission weakness“ there are only few effective devices entering the market. Efficacy therefore needs to be critically examined before purchase – as our histological studies were able to demonstrate. After reliable devices have been evaluated from the histological and clinical point of view, the additional combination of injection lipolysis and radial shock wave therapy represents a further progress in nonsurgical body contouring that has meanwhile become an integral part of everyday practice. Furthermore, the additional stimula-

tion of the lymphatic drainage through radial shock wave therapy has a positive influence on the final outcome. [9,10].

It is also important to point out that better results will be achieved during the colder months, since jitter-free thermogenesis can be activated directly by cold in brown and beige adipocytes [11].



Abb. 7: Z Lipo System (Zimmer MedizinSysteme).

REFERENCES

- Dieter Manstein D et al (2008) Selective cryolysis: A novel method of non-invasive fat removal. *Lasers in Surgery and Medicine* 40:595-604.
- Lisborg P. and Sandhofer M. and Blugermann G. (2005) Safe abdominoplasty in an office setting: The modified Avelar technique. *Plastic Surgery Practice*, March.
- Klein KB et al (2009) Non-invasive cryolipolysis for subcutaneous fat reduction does not affect serum lipid levels or liver function tests. *Lasers in Surgery and Medicine* 41:785-790.
- Ferraro GA et al. (2012) Synergistic effects of cryolipolysis and shock wave for noninvasive body contouring. *Asthet Plast Surg* 36(3): 666-679.
- Sandhofer M , Schauer P et al. (2013) Zur Kryolipolyse in der dermatologischen Praxis. *Kosmetische Medizin* 34: 100-109.
- Sandhofer M (2015) Radial shockwave therapy after cryolipolysis in cellulite and lymphedema – A field report. *Kosmetische Medizin* 36(1):12-13.
- Krueger N et al. (2014) Cryolipolysis for noninvasive bodycontouring: clinical efficacy and patient satisfaction. *Clin Cosmet Investig Dermatol.* 7:201-205.
- Tausch I, Kruglikov I (2015) The benefit of Dual-frequency ultrasound in patients treated by injections lipolysis. *J Clin Aesthet Dermatol* 8(8):42-46.
- Hunt J, Stork H (2013) Cryolipolysis and acoustic wave therapy. *Prime promotion*; September 2013; 112-113.
- Dierickx CC et al. (2013) Safety, tolerance and patient satisfaction with noninvasive cryolipolysis. *Derm Surg* 39(8):1209-1216.
- Sandhofer M et al. (2014) Die Kryolipothermie: kälteinduzierte, zitterfreie Thermogenesis zum nichtoperativen Bodycontouring. *Kosmetische Medizin* 1;18-21.